Rev Mex Neuroci ahora en CONACyT

Vol. 18, núm. 5 (septiembre-octubre de 2017)

Revista Mexicana de Neurociencia

Publicación oficial de la Academia Mexicana de Neurología A.C.

Revista Mexicana de Neurociencia; 18,5 (2017):92-99

Órgano Oficial de Difusión de la AMN

Academia Mexicana de Neurología, A.C.

www.revmexneuroci.com / ISSN 1665-5044

Case report

Gustavo Melo-Guzmán,[1] Víctor Hugo Escobar-de la Garma,[1] Omar Antonio Pérez-Morales,[1] Felipe Padilla-Vázquez,[1] Jorge del Bosque Méndez,[2] Rafael Mendizábal-Guerra.[1]

[1] *Servicio de Neurocirugía del Hospital Juárez de México. Ciudad de México.*
[2] *Servicio de Cirugía de Cabeza y Cuello del Hospital Juárez de México. Ciudad de México.*

Endovascular treatment of giant pseudoaneurysms of the cervical internal carotid artery: case report and review of the literature

Tratamiento endovascular de pseudoaneurismas gigantes de la arteria carótida interna cervical: a propósito de un caso y revisión de la literatura

Abstract

Introduction. Cervical internal carotid pseudoaneurysms are vascular lesions with high morbidity due to embolism and rupture. Surgery of these lesions is technically difficult, with low success rates. Nowadays, endovascular therapy has allowed favorable results with the use of covered-stents allowing vessel reconstruction.

Case report. A 45-year male with a past history of right blunt cervical trauma three years ago was admitted for study of a pulsatile right cervical mass. He reported headache 6 months before admission and progressive dysphagia with a protruding non-painful pulsatile mass in the right cervical region, causing dysphonia. A contrast-enhanced cervical computed tomography scan and the angiogram revealed a giant pseudoaneurysmal lesion in the cervical segment of the right internal carotid artery. The first endovascular procedure in which "stent in stent" technique was performed achieved 70% embolization of the aneurysm one year later. New angioplasty with a covered stent inside the previous ones achieved 90% embolization of the pseudoaneurysm. Eleven months later a new angiogram revealed definite embolization of the aneurysm.

Conclusion. The use of stents may be now a feasible and safe way of treating selected cases of giant pseudoaneurysms of the cervical internal carotid artery.

Keywords

pseudoaneurysm, endovascular therapy, internal carotid artery, stent in stent, covered stent.

Resumen

Introducción. Los pseudoaneurismas de la arteria carótida interna cervical son lesiones vasculares con alta morbilidad por su elevado riesgo de embolismo y ruptura. La cirugía de estas lesiones es técnicamente difícil, con tasas de éxito no siempre favorables. Actualmente la terapia endovascular ha demostrado resultados exitosos con baja morbimortalidad.

Reporte de caso: Paciente masculino de 45 años con el antecedente de trauma cervical contuso tres años atrás estudiado por masa cervical pulsátil derecha. Reportó cefalea frontal progresiva y disfagia insidiosa con la aparición de masa no dolorosa y pulsátil en la region cervical derecha condicionando disfonía. La angiotomografía computada cervical y angiografía reveló una lesión aneurismática gigante originada de la arteria carótida interna cervical derecha. Se realizó técnica de "stent in stent" obteniendo reconstruccion del vaso y trombosis inicial del 70% un año después. Nueva angioplastía con stent cubierto obtuvo embolización del 90%, lograndose trombosis y oclusion del 100% en el control angiográfico 11 meses después.

Conclusión. El uso de stents cubiertos puede ser una manera feasible y segura de tratar casos seleccionados de pseudoaneurismas gigantes en la arteria carótida interna cervical.

Palabras clave

pseudoaneurisma, terapia endovascular, arteria carótida interna, stent in stent, stent cubierto.

Corresponding author:
Víctor Hugo Escobar-de la Garma
Av. Instituto Politécnico Nacional 5160, Del. Gustavo A. Madero,
Col. Magdalena de las Salinas CP 07760. Ciudad de México, México.
Phone: (01) 55 5747 7560
E-mail: victorhe.delagarma@gmail.com, neuroendovascularmexico@gmail.com

Introduction

Carotid and vertebral pseudoaneurysms are rare vascular lesions which may occur due to disruption of the arterial wall after trauma, invasion by tumor, radiation necrosis or mycotic infection.[1-3]

Surgery to treat these lesions has fallen into disuse due to the great technical requirements involved, the significant morbidity and mortality associated with the procedure, and the low success rate.[4]

Endovascular therapy has substituted open procedures by being minimally invasive and presenting minimum morbidity as well as high technical success rates.[4] The embolization with coils and balloons has fallen into disuse and been substituted by covered stent placements, which allow to reconstruct the geometry of the parent vessels, recover their permeability, and achieve the subsequent regression of the pseudoaneurysm wall.[5]

The goal of this report is to describe the complex and progressive treatment of giant cervical pseudoaneurysms by endovascular approach and to review the literature.

Case report

A 45-year-old man was admitted to our hospital with a history of blunt trauma in the right cervical region five years before. An onset of insidious intermittent dry cough began in that period. Subsequently, it was accompanied by an intermittent oppressive frontal holocranial headache of progressively high intensity, partially attenuated with conventional analgesics. Months prior to visiting our hospital, he presented an increase in volume in the right pharyngeal region that produced changes in voice and limited swallowing, for which he consulted with an otorhinolaryngologist who, in turn, referred him to our institution.

In the physical examination we found a rounded mass, pulsatile and ill-defined, palpable in the right lateral region of the neck, non-painful, attached to deeper structures, of soft consistency, measuring approximately five centimeters in its wider diameter, extending to the oral cavity and the posterolateral oropharyngeal wall, obliterating 60% of it, making swallowing difficult.

Contrast-enhanced computer tomography of the cervical area (Figure 1) revealed obliteration of the right parapharyngeal space by a rounded mass of thick wall that captured contrast medium homogeneously and extended to the posterolateral oropharynx wall, connecting to the right internal carotid artery, and displacing the internal jugular vein dorsally and laterally. In sagittal and coronal reconstructions it was confirmed that the dilation depended on the right internal carotid artery in its cervical portion.

The initial cerebral pan-angiography revealed the existence of a giant saccular pseudoaneurysm of 40 x 50 mm in its diameters, rostrocaudal and mediolateral respectively, in the middle and upper third of the cervical segment of the right internal carotid artery, accompanied by the phenomenon of stealing from the right anterior cerebral artery. (Figure 2) Two months later, carotid angioplasty was performed using two stents (Wallstent™ Endoprosthesis, Boston Scientific, Natick, MA, USA) telescoped (stent in stent) at the point of the pseudoaneurysm (Figure 3) and a year later an angiographic control revealed thrombosis of 70% of the lesion and improvement of the blood flow of the anterior cerebral circulation. It was decided to undertake a new angioplasty with ePTFE (Expanded Polytetrafluoroethylene) covered stent of 8 mm x 8 cm (FLUENCY® plus Vascular Stent Graft, BARDpv Crawley, West Sussex, England) inside both Carotid Wallstents with immediate angiographic thrombosis result of 90% of the pseudoaneurysm and total reconstruction of the artery two years after the initial procedure (Figure 4).

Figure 1. Axial (a), coronal (b) and sagittal (c) contrast-enhanced CT of the cervical skull junction demonstrating the right parapharyngeal space blocked by a hyperdense round mass dependent on the ipsilateral cervical internal carotid artery with a thrombosed area at its medial and rostral periphery (white arrows).

Figure 2. Cerebral angiography of the right internal and external carotid artery in lateral projection demonstrating an irregular giant pseudoaneurysm (40 x 50 mm) originating from the middle and upper third of the cervical segment of the right internal carotid artery stealing from the anterior cerebral circulation ipsilateral (black arrows).

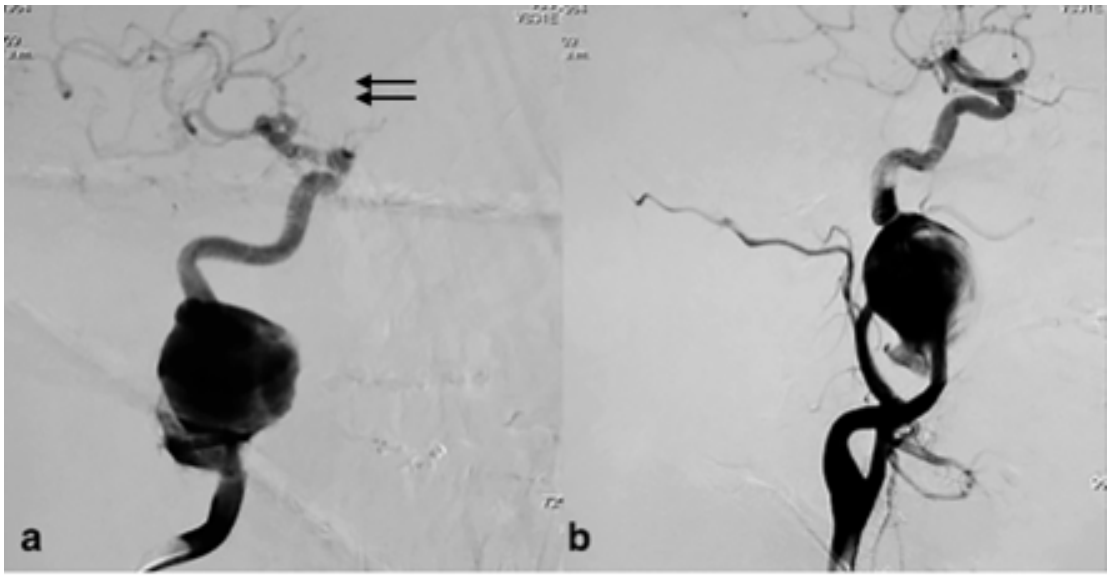

Figure 3. Internal carotid artery cerebral angiography in lateral projection revealing the placement of telescoped Wallstents (dotted arrows) in the cervical segment of the right internal carotid artery (a) and partial embolization of giant pseudoaneurysm after second angioplasty with covered stent (b).

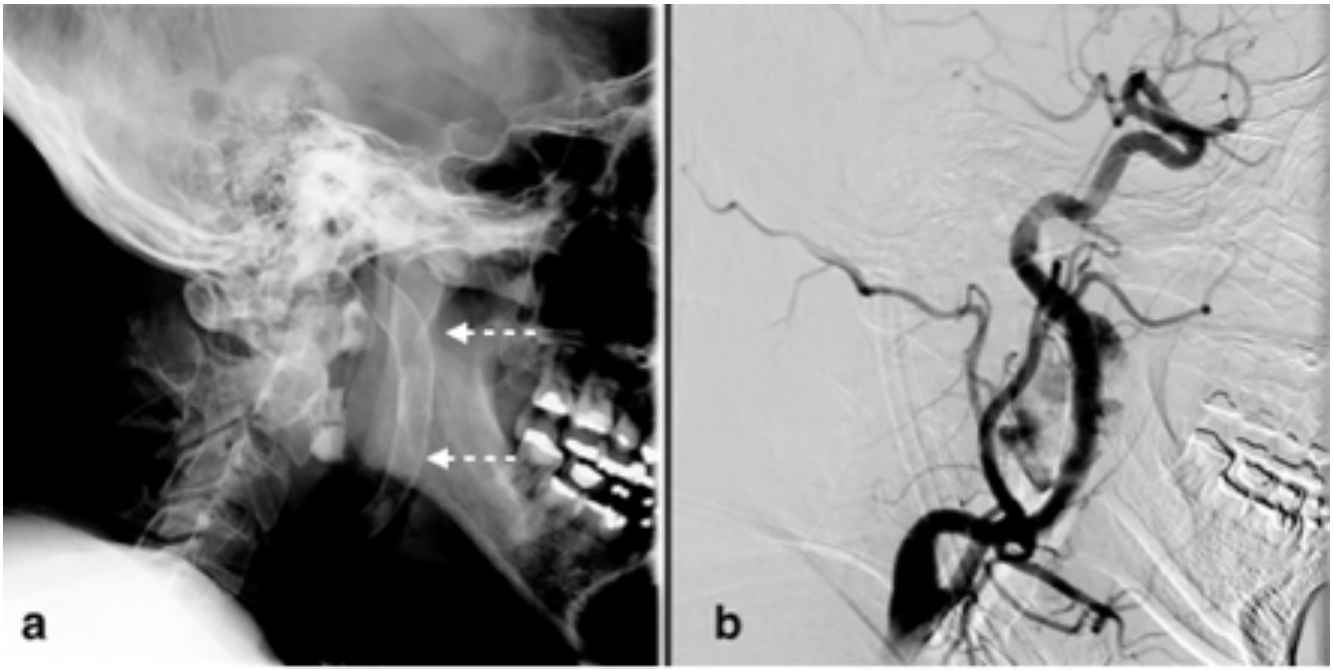

Figure 4. Control angiography with digital subtraction (a, d) and three-dimensional reconstructions (b, c, e, f) in AP and lateral projections two years after the initial procedure revealing preservation of arterial geometry with complete and definitive thrombosis of giant pseudoaneurysmal lesion in addition to the reestablishment of flow to the ipsilateral anterior cerebral circulation.

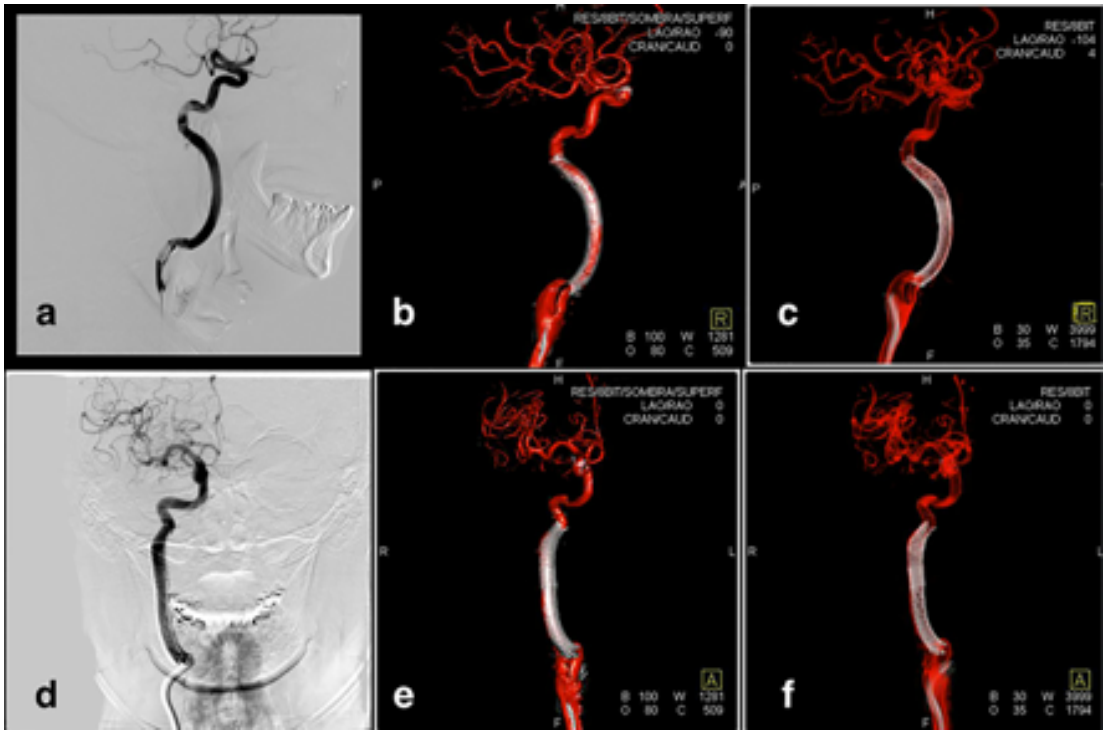

Discussion

Pseudoaneurysms are considered "false aneurysm lesions" because they consist of a single layer of fibrous tissue that envelops a sac of turbulent blood flow surrounded by a hematoma; these lesions differ from true aneurysms, which involve all three layers of the normal arterial vessel.[2] The sac of the pseudoaneurysm communicates directly with the arterial lumen. The true lumen of the parent vessel may be ruptured through dissection of the subintimal or subadventitial space.[6]

Usually, these lesions originate from a disruption of the arterial wall. Commonly, arterial dissections can lead to pseudoaneurysms by tearing the intima with extravasation of blood in the arterial wall. If the hematoma dissects the vessel between the intima and the media, the false lumen may occlude the true light of the parent vessel; if the dissection is between the media and the adventitia, the development of pseudoaneurysms is possible.[6]

The incidence of carotid pseudoaneurysms is 0.33%.[7] The frequency of these lesions is on the rise as result of increased detection by better imaging techniques.

The etiology of the trauma - whether it is contusive or penetrating - is the most frequent origin of these lesions.[8,9] Pseudoaneurysms will be found in a third of all cervical trauma injuries.[9] Carotid lesions are found in 3% of traumatic arterial lesions.[10] Among non-penetrating injuries, we can find lesions due to hyperextension, cervical rotation, direct contusion to neck injury, and intraoral trauma. Chaer *et al.* described in 2008 that 29% of arterial dissections result in pseudoaneurysms.[9]

Iatrogenic etiology has an incidence of 7.7%. It's been said that up to 1% of all diagnostic angiographies and 8% of endovascular therapeutic procedures can end the development of a pseudoaneurysm.[2]

Infectious etiology of the arterial wall is more frequently found to be due to Gram positive bacteria, currently assigning 22% to Staphylococcus aureus, 17% to Salmonella sp., 11% to Streptococcus sp., and 11% to Enterococcus sp. infections.[2]

Other less frequent causes are vasculitis (transmural inflammation with subsequent rupture), invasion of the arterial wall by neoplasms, drug abuse, and genetic disorders of connective tissue.[2]

Clinically these lesions can be silent, their clinical expression may be conditioned by secondary local factors secondary to the mass effect in giant lesions (dysphonia, cough, difficulty swallowing, and dysphagia in those with a parapharyngeal location) or epistaxis in lesions contiguous to the sphenoid sinus.[3] They can manifest systemically when there are complications derived from the pseudoaneurysm per se, such as rupture and massive hemorrhage, distal ischemia due to thromboembolism, sepsis in infectious cases, and occlusion of the parent vessel. The morbidity of carotid pseudoaneurysms is 80%.[7]

The first line diagnostic study in cervical lesions is the Doppler ultrasound with sensitivity of 94% and specificity of 97%.[2] The "Ying-Yang" sign suggests turbulent flow of blood inside the aneurysmal sac. This mode of treatment can detect the width of the neck of the lesion and the size of the hematoma surrounding the pseudoaneurysmal lesion.[2]

An angiotomography has a sensitivity of 95% and a specificity of 98.7%. Its main benefit is it differentiates between true aneurysmal lesions and pseudoaneurysms of intracranial location.[2]

Digital subtraction angiography is the second line image in these lesions. The information it provides is vital for the treatment to be established such as the size of the sac, the diameter of the neck, the affected vascular territory, and the final or distal artery affected.[2]

In 1999, Biff *et al.* designed the following scale of carotid lesions:[11]

I- Intimal lesions without hemodynamic relevance.

II- Dissections and hematomas with potential hemodynamic compromise.

III- Pseudoaneurysms.

IV- Arterial occlusions.

V – Complete section of vessel.

This scale is related to the prognosis and the appropriate treatment choice. The aggressive management of these lesions aims to prevent fatal hemorrhaging and thromboembolic events.[11]

Surgery of these lesions has always been characterized as technically very demanding. The different techniques include revascularization with bypass (internal carotid to middle cerebral via superficial temporal), direct repair of the arterial defect, and clipping. Clipping is high risk if the endothelialized fibrous sac is not found, as well as in lesions without a well-defined neck.[1,4,10] Total occlusion of the parent vessel is a commonly performed treatment with apparently good results; however, it has been associated with ischemic events in 5 to 22% post-occlusion even while securing anterior communicating artery collateral flow.12 This surgery's mortality is 1.44%.[10]

The advantages of endovascular therapy as a minimally invasive method make it a very attractive therapeutic strategy to treat these lesions effectively and safely. It was initially described as coil embolization,[13] but this technique has fallen into disuse because the devices may be subject to intra-aneurysmal migration and their effectiveness in broad-neck lesions is limited.[12-14] The use of stents has some advantages. It is a relatively simple and rapid procedure compared to surgery: the procedure, per se, is not in the aneurysmal sac, it preserves permeability in the parental vessel, promotes late thrombosis, and has a reduced mass effect compared with the use of coils.[4] The technical success rate is 98.2% with use of stents, and the complications include 9.1% of embolism and 1.8% of arterial dissections.[4]

The use of covered stents shares many of the advantages of other stents; however, some of the disadvantages are poor navigation due to their rigidity, higher risk of vascular perforations, intimal hyperplasia or subacute thrombosis, and secondary stenosis. The ideal covered stent would be flexible, very elastic, with high adherence to the vascular wall, and self-expanding (because of the potential of collapse under the internal carotid's high pressure in those expandable by balloon).[1,4,6,10,15]

Non-covered stents promote late thrombosis which is sometimes incomplete; however, in this specific case, we used the telescoping technique, whose objective is the reconstruction of the artery's geometry to provide the necessary support to prevent the possible bending of a single covered stent.

Conclusion

The endovascular treatment of giant pseudoaneurysms of the internal carotid artery with cervical stents can be an effective and safe method these days. Reconstruction of the parent vessel lumen may require the use of uncovered telescoping stents to provide the support and structure required to prevent eventual bending of the covered stent.

Conflict of interest

The authors state there are no conflicts of interest related to the writing of this article.

Funding

The authors state no funding was received from any person or company to create this article.

References

1. Yi AC, Palmer E, Luh GY, Jacobson JP, Smith DC. Endovascular treatment of carotid and vertebral pseudoaneurysms with covered stents. *AJNR Am J Neuroradiol.* 2008; 29(5):983-7.
2. Keeling AN, McGrath FP, Lee MJ. Interventional radiology in the diagnosis, management, and follow-up of pseudoaneurysms. *Cardiovasc Intervent Radiol.* 2009; 32(1):2-18.
3. Gupta V, Niranjan K, Rawat L, Gupta AK. Stent-graft repair of a large cervical internal carotid artery pseudoaneurysm causing dysphagia. *Cardiovasc Intervent Radiol.* 2009; 32(3):558-62.
4. Alaraj A, Wallace A, Amin-Hanjani S, Charbel FT, Aletich V. Endovascular implantation of covered stents in the extracranial carotid and vertebral arteries: Case series and review of the literature. *Surg Neurol Int.* 2011;2:67.
5. Lim J, Suh SH, Lee KY, Hong CK, Park SW. Endovascular treatment of iatrogenic intracranial pseudoaneurysm following stent angioplasty. *J Neuroimaging.* 2012; 22(2):194-6.
6. Scavee V, De Wispelaere JF, Mormont E, Coulier B, Trigaux JP, Schoevaerdts JC. Pseudoaneurysm of the internal carotid artery: treatment with a covered stent. *Cardiovasc Intervent Radiol.* 2001; 24(4):283-5.
7. Fusonie GE, Edwards JD, Reed AB. Covered stent exclusion of blunt traumatic carotid artery pseudoaneurysm: case report and review of the literature. *Ann Vasc Surg.* 2004; 18(3):376-9.
8. Zhou B, Zhou T, Arous EJ, Liu W. A giant common carotid artery pseudoaneurysm after penetrating injury. *J Vasc Surg.* 2012; 55(1):240-1.
9. Chaer RA, Derubertis B, Kent KC, McKinsey JF. Endovascular treatment of traumatic carotid pseudoaneurysm with stenting and coil embolization. *Ann Vasc Surg.* 2008; 22(4):564-7.
10. Yeh CH, Lin MS, Chiu MC, Chen CH, Pai YL. Endovascular treatment of a huge cervical carotid artery pseudoaneurysm with Wallgraft prosthesis. *Ann Vasc Surg.* 2011; 25(2):265 e1-3.
11. Biffl WL, Moore EE, Offner PJ, Brega KE, Franciose RJ, Burch JM. Blunt carotid arterial injuries: implications of a new grading scale. *J Trauma.* 1999; 47(5):845-53.
12. Lv X, Jiang C, Li Y, Lv M, Zhang J, Wu Z. Intracranial pseudoaneurysms, fusiform aneurysms and carotid-cavernous fistulas. Repair with percutaneous implantation of endovascular covered stents. *Interv Neuroradiol.* 2008; 14(4):435-40.
13. Maras D, Lioupis C, Magoufis G, Tsamopoulos N, Moulakakis K, Andrikopoulos V. Covered stent-graft treatment of traumatic internal carotid artery pseudoaneurysms: a review. *Cardiovasc Intervent Radiol.* 2006; 29(6):958-68.
14. Li MH, Li YD, Gao BL, Fang C, Luo QY, Cheng YS, *et al*. A new covered stent designed for intracranial vasculature: application in the management of pseudoaneurysms of the cranial internal carotid artery. *AJNR Am J Neuroradiol.* 2007; 28(8):1579-85.
15. Riesenman PJ, Mendes RR, Mauro MA, Farber MA. Endovascular exclusion of an external carotid artery pseudoaneurysm using a covered stent. *Cardiovasc Intervent Radiol.* 2007; 30(5):1025-8.

Revista Mexicana de Neurociencia, 2017; 18(5): 92-99
www.revmexneuroci.com